

# Transcutaneous Temperature Controlled Radiofrequency (TTCRF) for the Treatment of Menopausal Vaginal/Genitourinary Symptoms

GUSTAVO LEIBASCHOFF, MD  
SPECIALIST

GYNECOLOGY AND OBSTETRICS DEPARTMENT  
UNIVERSITY OF BUENOS AIRES SCHOOL OF MEDICINE  
BUENOS AIRES, ARGENTINA

PABLO GONZALEZ IZASA, MD  
SPECIALIST

GYNECOLOGY AND OBSTETRICS DEPARTMENT  
MILITARY UNIVERSITY OF COLOMBIA  
HEAD CHIEF

UROGYNECOLOGY DEPARTMENT  
HOSPITAL UNIVERSITARIO SAN JORGE  
PEREIRA, COLOMBIA

JOSE LUIS CARDONA, MD  
SPECIALIST

PATHOLOGY DEPARTMENT  
UNIVERSIDAD TECNOLOGICA  
PEREIRA, COLOMBIA

JOHN R. MIKLOS, MD  
SPECIALIST

FEMALE PELVIC MEDICINE AND RECONSTRUCTIVE SURGERY  
DEPARTMENT  
INTERNATIONAL UROGYNECOLOGY ASSOCIATES OF ATLANTA  
BEVERLY HILLS, CALIFORNIA AND  
DUBAI, UNITED ARAB EMIRATES  
PROFESSOR

OBSTETRICS AND GYNECOLOGY DEPARTMENT  
EMORY UNIVERSITY  
ATLANTA, GEORGIA

ROBERT D. MOORE, DO, FACOG, FPRMS, FACS  
SPECIALIST

FEMALE PELVIC MEDICINE AND RECONSTRUCTIVE SURGERY  
INTERNATIONAL UROGYNECOLOGY ASSOCIATES OF ATLANTA  
BEVERLY HILLS, CALIFORNIA AND DUBAI,  
UNITED ARAB EMIRATES  
PROFESSOR

OBSTETRICS AND GYNECOLOGY DEPARTMENT  
EMORY UNIVERSITY  
ATLANTA, GEORGIA

## ABSTRACT

**Objective:** The aim of this study was to evaluate the effects of non-ablative, monopolar transcutaneous temperature controlled radiofrequency (TTCRF) technology in the treatment of postmenopausal women suffering from genuine stress urinary incontinence (SUI) related to menopause and to evaluate histological changes vaginally associated with the treatment.

**Materials and Methods:** Subjective and objective symptoms of SUI were assessed in study subjects before and after TTCRF, (1 treatment every 30 days, for 3 months; n=10) and compared with the effects of a placebo treatment on a control group of demographically similar women (n =10). SUI was subjectively evaluated with subjective Urogenital Distress Inventory (UDI-6) and with the International Consultation on Incontinence

Questionnaire-Urinary Incontinence Short Form (ICIQ-UI SF) before and after TTCRF treatments and objectively with cough stress test. Vaginal health was evaluated with the Vaginal Health Index (VHI) score and visual analogue score (VAS) for dyspareunia and dryness. Punch biopsies were obtained at the urethra-vesical junction in the anterior compartment, before and at the end of the treatment protocol. Basic and histochemical staining methods were used.

**Results:** In subjects suffering SUI, TTCRF treatment was associated with a significant ( $p < 0.01$ ) improvement of ICIQ-SF and UDI-6 scores. Seven of 10 patients (70%) had a negative cough stress test after the treatment protocol. Improvements were maintained up to the 12th week of follow-up. The results were supported by the positive histologic changes seen vaginally in women suffering from postmenopausal vaginal atrophy. TTCRF was well tolerated with no complications reported in study patients.

**Conclusion:** TTCRF treatment in postmenopausal women suffering from SUI showed significant improvement in both objective and subjective symptoms. Vaginal health scores also improved as did VAS for dryness and dyspareunia. We feel these improvements were related to histological changes related to improvement in vaginal atrophy that were not observed in placebo patients.

## INTRODUCTION

Female genuine stress urinary incontinence (SUI) affects women of child-bearing age as well as peri- and postmenopausal women. As women age, it is well known that they may suffer from increasing genitourinary symptoms including SUI, urinary urgency and frequency, urinary urge incontinence, as well as vaginal dryness and atrophy. These symptoms have been theorized to be secondary to some of the histologic changes seen vaginally that are related to a decreasing level of estrogen. The term geni-

tourinary syndrome of menopause (GSM)(1) emerged following a consensus conference held in May 2013. GSM is a more descriptive term than vulvovaginal atrophy (VVA), however, and does not necessarily imply pathology. There are some concerns that GSM is all encompassing and includes not only symptoms resulting from estrogen deficiency, but also those arising from the effects of aging and other processes on the bladder and pelvic floor. Focusing on symptoms related to estrogen deficiency, the update provides a practical guide for health and allied health professionals on the impact of GSM on women and their partners, assessment,

management, and areas for future research.<sup>2</sup>

GSM has been affiliated with a wide range of urogynecological symptoms including urinary incontinence as well as vaginal symptoms related to estrogen depletion associated with the aging process. In women going through menopause, there has been shown to be a decrease in both diameter and quantity of peri-urethral striated muscle which may be responsible for intrinsic and extrinsic continence mechanisms. Additionally, collagen I and III content and quality at the level of the endo pelvic fascia is affected and has been shown to have a close relationship with

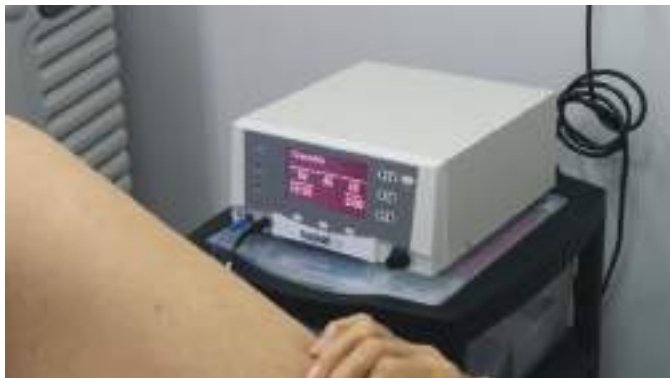

Figure 1. TTCRF device.

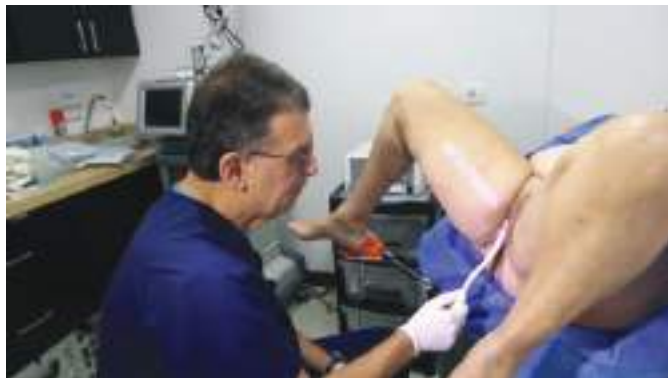

Figure 2. Vulvar application of the special ergonomic probe for vulva and vagina.

pelvic floor dysfunction, including SUI.<sup>3-5</sup>

Available treatment options to date for SUI and postmenopausal urinary symptoms have included: behavioral therapy with pelvic floor exercises and physical therapy, bladder training and timed voiding, and pharmacologic therapy and/or surgical intervention. Pharmacologic therapy has been limited to anticholinergic agents for urinary urgency/frequency, estrogen use, either local or systemic, for vaginal atrophy symptoms. Unfortunately, vaginal estrogen therapy has not been shown to significantly improve symptoms of urgency/frequency or SUI by itself, however, it is well known to improve vaginal health and help with symptoms of atrophy and dryness and sexual dysfunction related to these deficits. Surgical options for SUI include sub-urethral mesh tape slings (SUS), traditional pub-ovaginal slings, or bladder neck suspension surgery such as the Burch colposuspension. These surgical options have all been shown to have cure rates in the range of 80–90% for SUI, however, they are all invasive surgical interventions with inherent risks of invasive surgery. Many women today are not willing to risk surgical intervention or do not want to have to undergo the recovery that is necessary with surgery and therefore are seeking non-surgical alternatives to treat SUI and associated symptoms of GSM. Additionally, with the recent negative public perception of mesh use in pelvic floor surgery and incontinence following the FDA safety notifications starting in 2011, women are shying away from surgery—specifically mesh use in surgery—and are seeking less invasive treatment options for urinary leakage. Despite position statements from many organizations, including the American Urogynecologic Society and the American Urologic Association, stating that mesh tape slings are considered to be the gold standard treatment for female SUI, women are still looking for less invasive alternatives.

TTCRF treatment has been shown to improve collagen levels in dermis and result in clinical improvement in skin tightening and the aesthetic appearance of skin in different parts of the body.<sup>6,7</sup> More recently, a vaginal probe to deliver this technology to the vaginal walls has been developed and has shown evidence of improving the health of the



Figure 3. Punch biopsy.

vaginal epithelium leading to improved vaginal health and improvement in symptoms such as vaginal dryness, urinary symptoms, and sexual function.<sup>8</sup>

### MATERIALS AND METHODS

This prospective descriptive double-blind randomized controlled trial was performed at Hospital Universitario San Jorge Pereira Colombia. This single-site study recruited patients attending the Urogynecology unit. Postmenopausal women presenting at the clinic were given a survey regarding their symptoms of stress urinary incontinence and vaginal relaxation syndrome. Those women that answered positive to the presence of these symptoms were recruited to be involved in the study.

After gaining informed consent, 20 patients were included in this prospective randomized descriptive study.

Patients all presented with symptoms of stress urinary incontinence and/or vaginal laxity including the presence of passing vaginal winds or water entrapment, which are common problems reported by patients with wide vagina. Stress urinary incontinence was confirmed with the presence of a positive cough stress test with 300cc in the bladder, in the supine position.

### Primary outcomes

Symptoms were assessed relating to the genitourinary syndrome of menopause subjective and objective cure of stress urinary incontinence by the International Consultation On Incontinence Short Form (ICQ-SF),<sup>9,10</sup> and the Urogenital Distress Inventory (UDI-6)<sup>11</sup> in an attempt to demonstrate histological changes related to the vaginal trophism restoration at the urethra-vesical junction, correlated to the subjective and objective cure of stress urinary incontinence.

Table I  
Demographics and clinical variables

	Active Group	Control Group
<b>Age</b>	55+/-5,8	56,9 +/- 3,1
<b>Parity</b>	2,4 +/- 0,8	2,3 +/- 0,8
<b>Menopause</b>	n=10	N=10
<b>HRT</b>	2–10 (20%)	3–10 (30%)
<b>Sexual Activity</b>	N=10	N=10
<b>Urogynecology Examination</b>		
<b>Urethral hypermovility</b>	N=10	N=10
<b>SUI</b>	N=10	N=10
<b>Pelvic Organ Prolapse POP -Q</b>		
<b>Stage 0</b>	0	0
<b>Stage 1</b>	82,31	17,69
<b>Stage 2</b>	42,33	57,67
<b>Stage 3</b>	0	0

**Table II**  
**Stress Urinary Incontinence International Consultation on Incontinence Questionnaire-Urinary Incontinence Short Form (ICIQ-UI SF) at baseline and at 12 weeks after TTCRF protocol in vaginal walls expressed as mean value SD**

ICQ-SF	Active Group (AG) p 0.017	Control Group (CG)
Patients	N=10	N=10
Baseline	17,3 +/- 0,78	17,1 +/- 0,94
12-week follow-up	11,4 +/- 0,66	16,5 +/- 2,0

**Table III**  
**Urinary Incontinence Urinary Distress Inventory (UDI-6) Urinary Incontinence Short Form before and after TTCRF protocol, expressed as mean value SD**

UDI-6	Active Group	Control Group
Baseline	33,7 +/- 12,5	32,91 +/- 5,45
12-week follow-up	16,2 +/- 6,0	33,3 +/- 5,6
P	(p<0.017)	

**Table IV**  
**Vaginal Health Index (VHI) Scores**  
 Vaginal health evaluated by Vaginal Health Index, Gloria Bachman et al., at baseline and at 12 weeks after TTCRF protocol, expressed as mean value SD

VHI	Active Group	Control Group (CG)
Baseline	11,5 +/-0,67	11,6 +/- 0,66
12-week follow-up	19,3 +/-2,01	11,8 +/- 2,1

**Secondary outcomes**

Assessment of clinical changes related to vaginal trophism were evaluated by clinical examination and change of scores in the Vaginal Health Index (VHI) by Gloria Bachman et al.<sup>12</sup> Treatment satisfaction was evaluated by the visual analogue scale (VAS)<sup>13</sup> comparing baseline values to the end of the treatment protocol values as well as vulvar laxity and changes in the quality of the connective tissue with cosmetic improvement in vulva.

The active group subjects were followed prospectively in a three month follow up to treatment with TTCRF

protocol in the vaginal walls. The control group did not have an active treatment, but instead a sham treatment protocol. Statistical analysis was performed using SPSS 11.5.1 (SPSS, Chicago, Illinois). Quantitative variables were obtained using the following parameters: mean, median, and standard deviation in both groups, the qualitative variables were compared with the  $\chi^2$  distribution formula of Pearson and “Student’s t”, both with an expected significant value of  $p \leq 0.05$ ; the number of the sample was 20 women who entered the study active group n=10 and the control group n=10.

*Inclusion criteria*

1. Early stages of SUI
2. Positive cough stress test
3. Non-previous treatments
4. Voluntary participation
5. SUI impact on quality of life
6. SUI-related sexual dysfunction
7. No prolapse associated POP Q> 1 anterior compartment<sup>14</sup>
8. Menopause

**Exclusion Criteria**

1. Non-adequately classified
2. Previous surgery
3. Recurrent lower urinary tract infection
4. BMI > 35

**Treatment protocol**

Treatment protocol of the active treatment group receiving TTCRF was as follows:

Technique: Utilized the specially designed vaginal ThermiVa® (Thermi-Aesthetics, Irving, Texas) probe and generator—the active portion of the probe is passed slowly and with wide sweeps of the desired zone of treatment for three to five minutes until the tissue is gradually heated to the therapeutic level of 40–45°C. Ultrasound gel is utilized during the treatment to the tissues.

**Zones of treatment**

- ◆ Labia majora and Labia minora: Treated bilaterally from the lowest edge of the mons pubis to the perineal body and laterally to the crural folds, including the clitoral hood.
- ◆ Vaginal canal: Treatment of the vaginal sidewalls as well as anterior and posterior vaginal walls moving in sweeping half-moon motion, and in and out. From 2cms to 10cms deep (or greater depending on vaginal length of patient) area.
- ◆ Warm-up time per each zone was approximately 30 seconds to 3 minutes. Once a therapeutic temperature of 40–45°C was reached, treatment time was three to five minutes per zone. If the patient could not tolerate the temperature, the temperature was decreased (maintaining minimal treatment temperature) and/or a larger surface of tissue was treated (i.e., increasing size of sweeping or movement arc) and multiple passes in the same area was avoided. Mild to moderate pressure was applied during treatment, while maintaining

full contact with the skin. Treatment began with small sweeping movements and increased to larger/longer movements. The entire treatment zone was heated to a uniform probe temperature of 40–45°C.

Patients randomized to the non-treatment group were treated using the same protocol as above, however, the generator was not turned on, therefore, they received no heating or RF therapy from the vaginal probe during the treatment (Figs. 1 and 2).

### Protocol

- ◆Pre-Tx photos
- ◆Biopsy pre-treatment
- ◆No anesthesia
- ◆Five minutes per area /Total treatment time of 30 minutes
- ◆Heat to 40–45°C
- ◆Three total treatments
- ◆Four weeks apart
- ◆Photos, histology, histochemical and questionnaires at set intervals (what intervals were used specifically)
- ◆Placebo/non-treatment group—same protocol but no active RF utilized during treatment

### Histological study

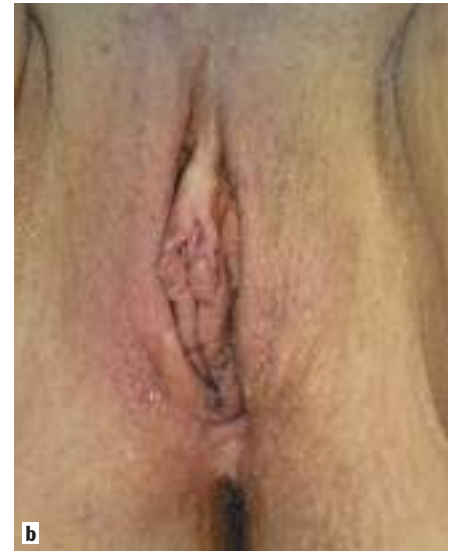Biopsies were obtained at the urethra-vesical junction in the anterior compartment with a dermatology punch, before and at the end of the treatment protocol. Biopsies of the skin of the vulva were also obtained, before and after the protocol in order to corroborate histological changes and cosmetic improvement (Fig. 3). The pathologist was blinded to the source of the biopsy.

Two histologic preparations were utilized to analyze the biopsy samples: Hematoxylin and eosin (H&E) and modified Masson's trichrome.

Visual analogue scale (VAS)	Active Group	Control Group
<b>Baseline</b>	6,6 +/-0,66	6,4 +/- 0,8
<b>12-week follow-up</b>	2,9 +/-0,83	6,3 +/- 0,64



**Figure 4a.** Before treatment with ThermiVa® (TTCRF).



**Figure 4b.** After first session with ThermiVa® (TTCRF).

### Hematoxylin and Eosin (H&E)

The H&E prep of the nucleus and parts of the cytoplasm that contain RNA were stained in one color (purple), and the rest of the cytoplasm were stained in a different color (pink). Most proteins in the cytoplasm are basic, so eosin binds to these proteins and stains them pink. This includes cytoplasmic filaments in muscle cells, intracellular membranes, and extracellular fibers.

### Modified Masson's trichrome staining in collagen evaluation in wound healing

The most important is collagen fiber as it plays a dominant role in maintaining the structural integrity of wound healing. The purpose of the trichrome stain is primarily to demonstrate collagen and muscle in normal tissue. Trichrome stains are used to distinguish collagen from muscle and aid in the



**Figure 5a and b.** Before and after one session with TTCRF.

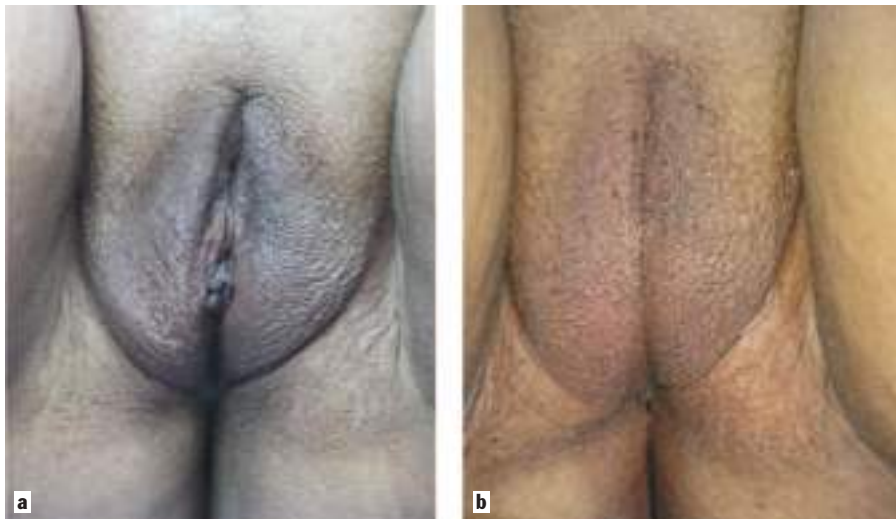

Figure 6a and b. Before and after three sessions of TTCRF.

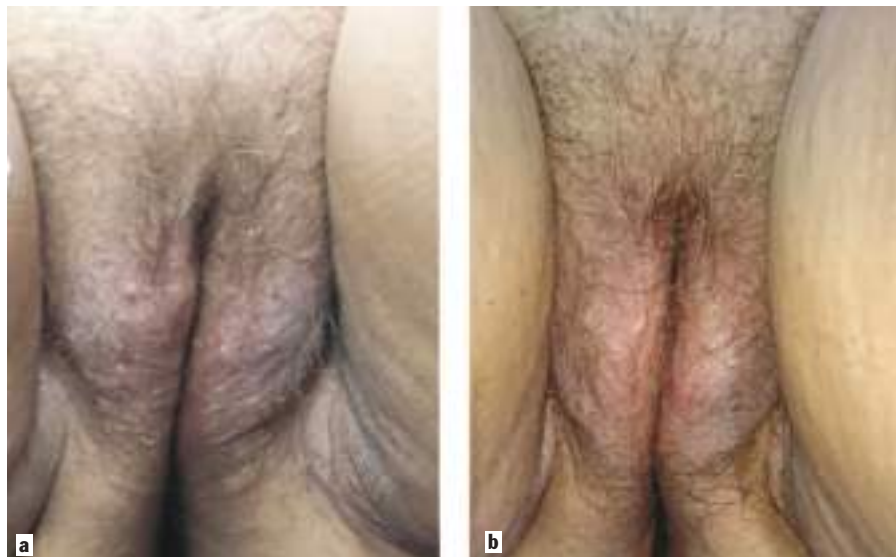

Figure 7a and b. Before and after three sessions of TTCRF.

diagnosis of fibrotic changes. It is also used to demonstrate increased collagen deposition in tissue or to indicate fibrotic changes. This method was modified from Kiernan (2008).<sup>15,16</sup>

### Ethical considerations

Patients recruited for this study were volunteers from the Urogynecology unit. They offered to participate prior to obtaining informed consent and a written authorization to be included in their medical records according to Helsinki declaration, Belmont report, CIOMS rules, GPC/ICH, and 008430 resolution of Colombia government stabilised on October 4, 1993. The present investigation considered minimal risk or beyond minimal risk as follows:

- ◆ Adjust and briefly explain the ethical principles that warrant investigation according to international standards.
- ◆ Based on previously conducted experiments on animals in laboratories and other scientific facts that show a secure intervention in humans.
- ◆ Clearly express the risks and security guarantees to participants.
- ◆ Having the written informed consent of research subjects or their legal representatives.
- ◆ Relates the experience of researchers and the responsibility of a health entity.

### Informed consent

The type of informed consent used was specifically designed for the treat-

ment of menopausal vaginal atrophy and SUI with TTCRF.

## RESULTS

Demographics and clinical variables of the two groups are seen in Table I. Twenty patients completed the study, 10 in the active group and 10 in the control group. The baseline QOL scores as well as VHI and VAS were statistically not different between the two groups. QOL outcomes were analyzed utilizing the validated tools UDI-6, International Consultation on Incontinence-Urinary Incontinence Short Form (ICIQ-UI SF), and VAS before and at least three months after three sessions of TTCRF treatment protocol in the vaginal walls. Vaginal health was evaluated via the VHI score over the same timeframe. Treatment was well tolerated by all patients and no patient discontinued treatment due to adverse events.

### Urinary incontinence

Urinary leakage symptoms were evaluated by the use of the ICIQ-UI SF as well as UDI-6. Baseline scores were not different between the treatment group and the placebo group. Follow-up scores in the treatment group showed statistically significant improvement in urinary leakage symptoms, whereas the control group showed no improvement in scores (Table II and III).

Regarding the 20 patients suffering from SUI related to GSM, TTCRF treatment induced improvement in the scores of the ICIQ-UI SF before and after the treatment in the treatment group (17.3 +/- 0.78 to 11.4 +/- 0.66) (Table II).

UDI-6 also revealed statistical improvement from baseline to the end of the treatment in the active group (37.5 +/- 7.2 to 16.23 +/- 6.6). No improvement was seen in the control/placebo group. As an objective evaluation, we found that 7 of 10 patients in the treatment group (70%) had a negative stress test after the treatment protocol, a positive stress test was maintained in the control group in all patients (Table III).

### Vaginal health

Vaginal health scores significantly

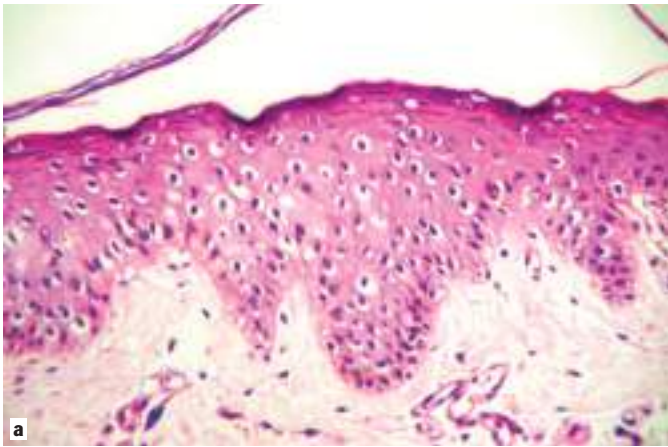


Figure 8a. Labia majora pre-TTCRF H&E. Stain demonstrates squamous epithelium with low surface coating, thin granulosa layer.

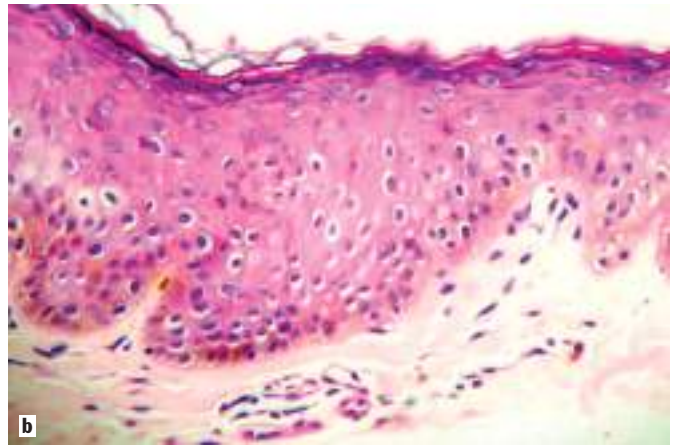


Figure 8b. Labia majora post-complete-TTCRF H&E. Stain demonstrates epidermis with increase of the number of cell layers (granulosa), proper maturation of the epithelium.

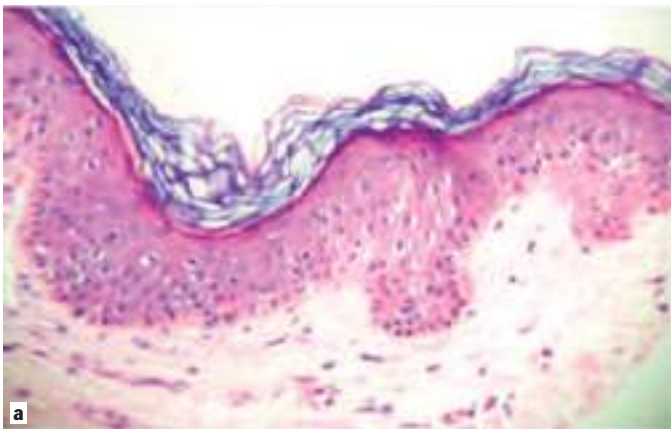


Figure 9a. Vagina pre-TTCRF (H&E).

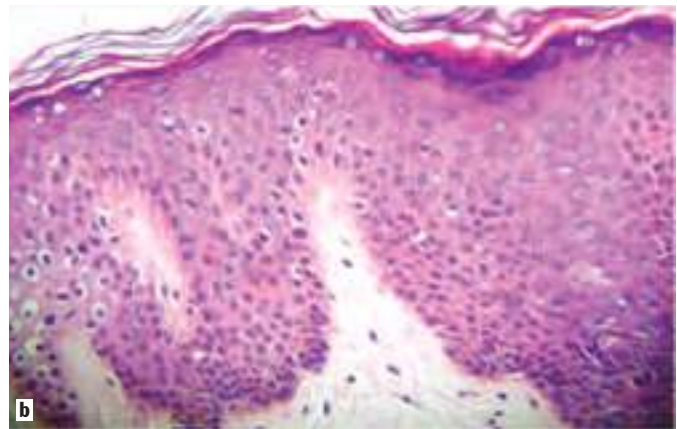


Figure 9b. Vagina post-TTCRF (H&E) anterior vaginal wall urethra vesical junction.

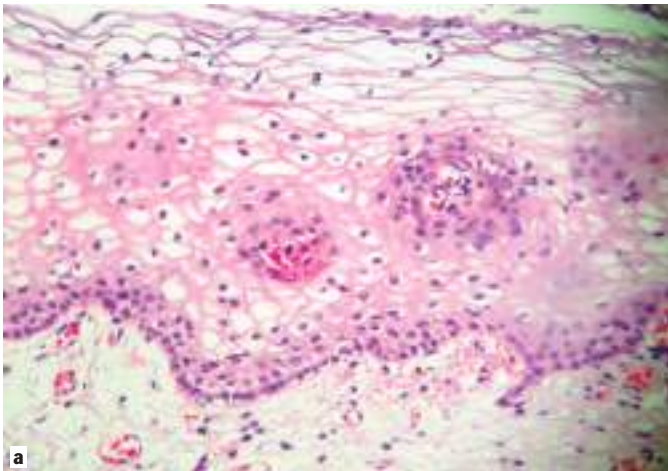


Figure 10a. Vagina pre-TTCRF. Pre-epithelium with few cell layers and poor maturation.

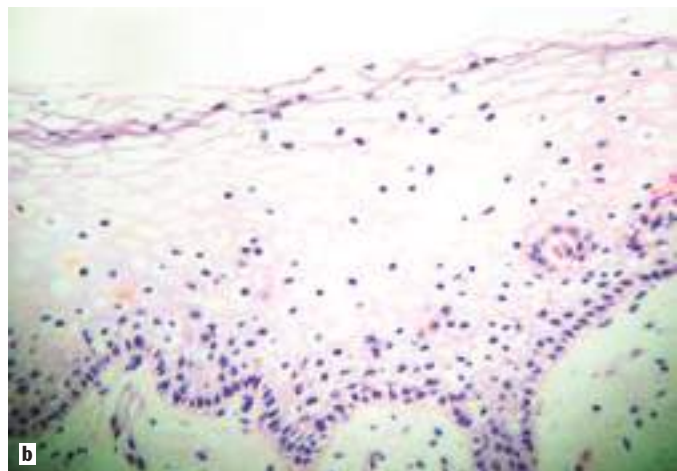


Figure 10b. Vagina post-TTCRF. Post-epithelium with increased cellularity maturation and the epithelium growing toward the surface, with more basal cells and an increase in the thickness of the stroma.

improved utilizing the VHIS in the treatment group; however, the scores were unchanged in the control group (Table IV).

In the follow up period, the dryness and dyspareunia values were  $6,6 \pm 0,66$  (AG) and  $6,4 \pm 0,8$  (CG) four

weeks after TTCRF, and scores improved to  $2,9 \pm 0,83$  in the active group. The VAS values in the control group did not show any significant changes during the treatment period— $6,4 \pm 0,8$  (CG)  $6,3 \pm 0,64$  (CG) (Figs. 4–16, Table V).

## DISCUSSION

TTCRF has been shown to be a proven technology and have numerous advantages for the treatment of skin laxity. RF has been established as an

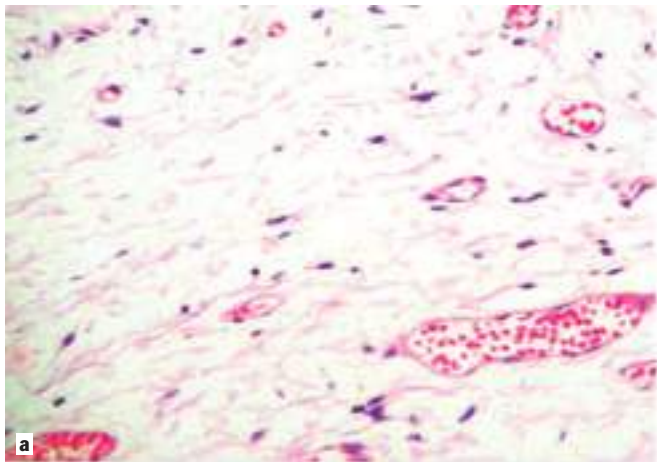


Figure 11a. Vaginal stroma pre-TTCRF. Lax stroma with little collagen.

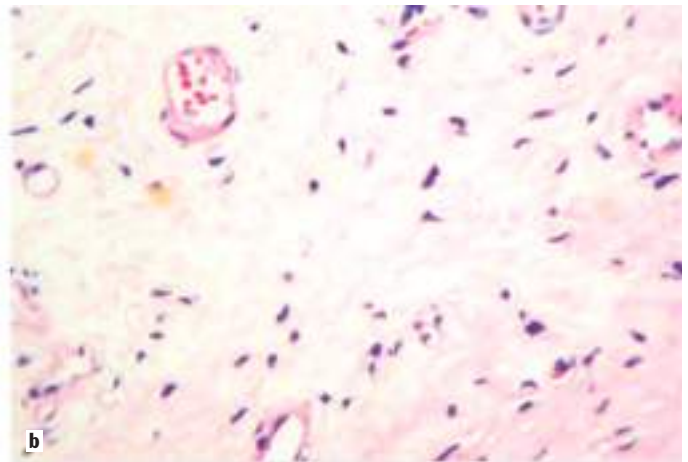


Figure 11b. Vaginal stroma post-TTCRF. Stroma increased the number of fibroblasts and collagen.

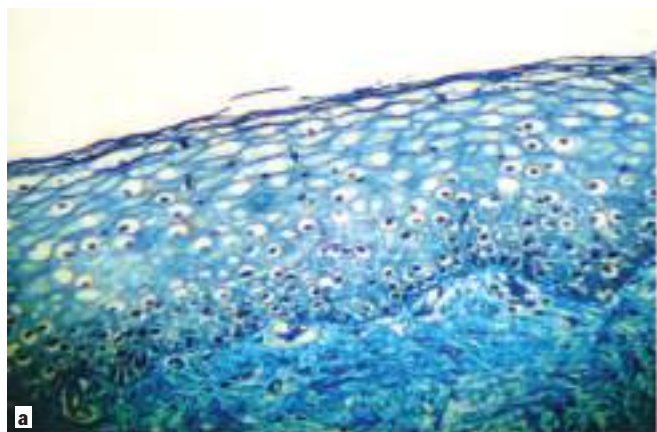


Figure 12a. Vagina histochemical Masson's stain modified pre-TTCRF: flattened epithelium, lax stroma.

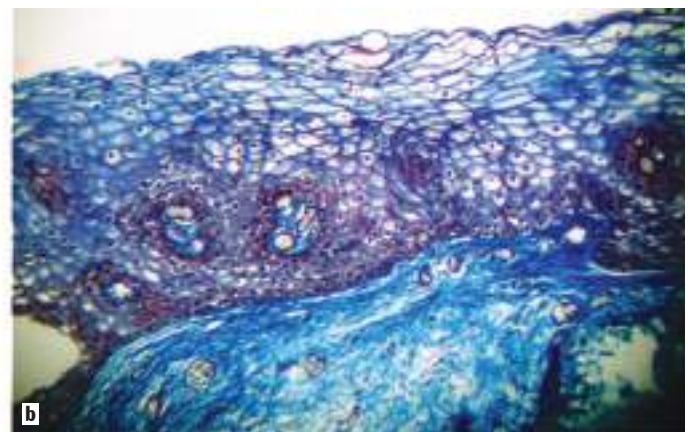


Figure 12b. Post-TTCRF. Epithelium increased number of maturing layers to the surface as well as collagen.

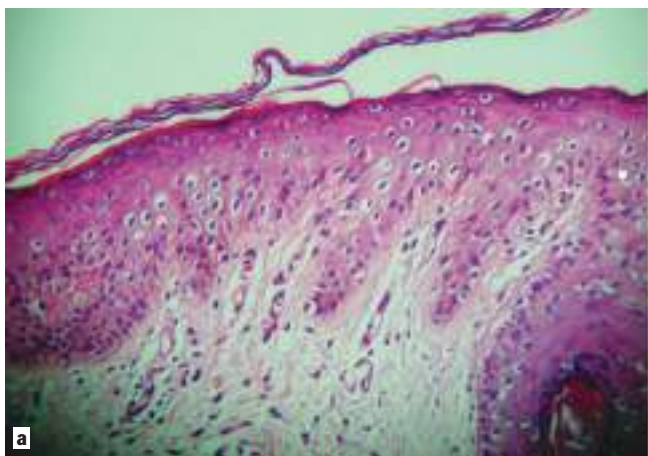


Figure 13a. Labia majora epithelium pre-TTCRF H&E stain.

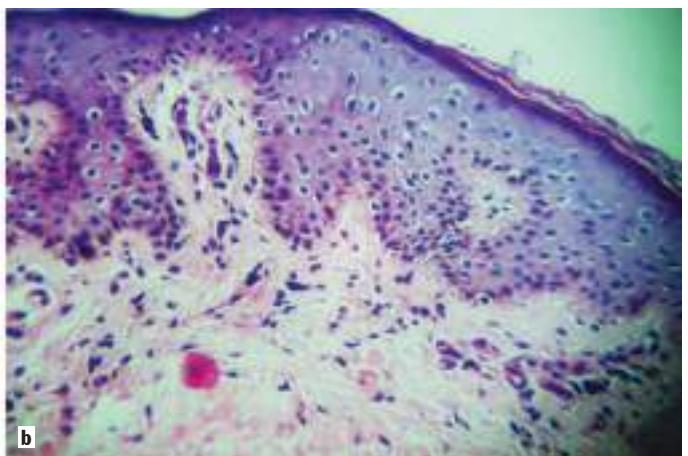


Figure 13b. Labia majora epithelium post-TTCRF H&E. Epithelium with maturation, increased presence of papillae, and greater presence of fibroblasts stromal more loose.

excellent modality for tissue tightening via stimulation of neocollagenesis, denaturation of collagen, contraction, and activation of the healing cascade. Numerous studies in dermatology<sup>17</sup> have demonstrated tissue contraction and have determined a therapeutically

ideal temperature range 40–45°C). Neocollagenesis (via the healing cascade) is stimulated without causing unnecessary damage to the skin or integral tissue structures.<sup>18</sup> Low-dose RF continues to be used in other areas of medicine for the treatment of facial and

neck skin laxity as well as periorbital rhytides. ThermiVa® (TTCRF) is the first and only temperature controlled radio frequency system used for non-surgical dermatological application in aesthetics and other medical specialties (Fig. 17).<sup>19</sup>



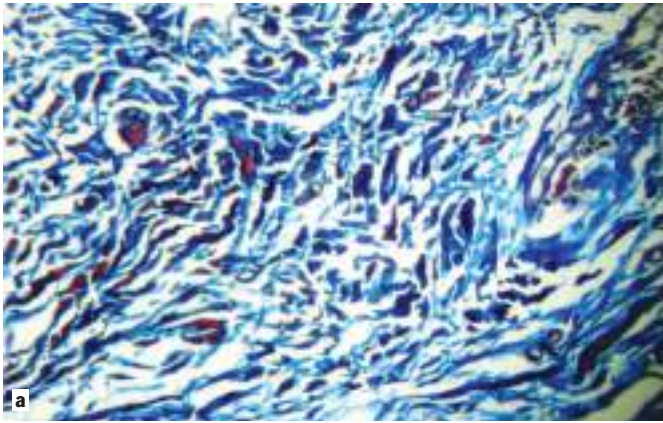


Figure 14a. Labia majora vulva stroma masson's modified pre-TTCRF.




Figure 14b. Labia majora vulva stroma masson's modified post-TTCRF. Shows increased presence of collagen.

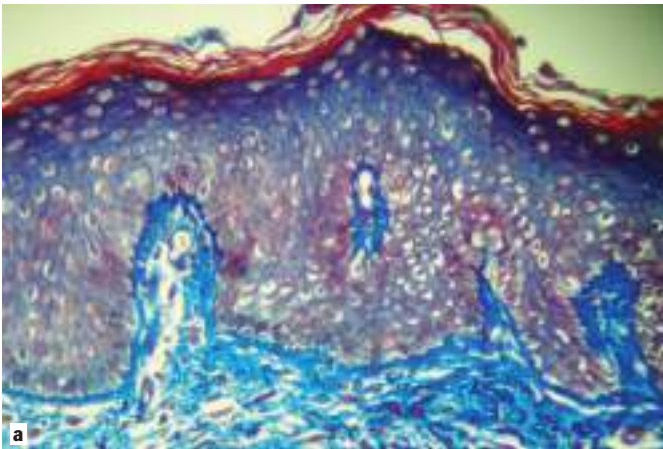


Figure 15a. Labia majora vulva epithelium masson's modified pre-TTCRF.

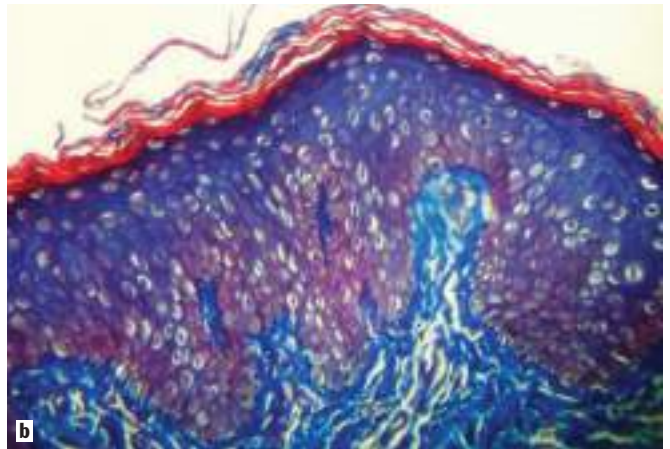


Figure 15b. Labia majora vulva epithelium masson's modified post-TTCRF. Epithelium with increased activity in the basal layer, further maturation of the epithelium, and the presence of glycogen. Intense blue collagen.

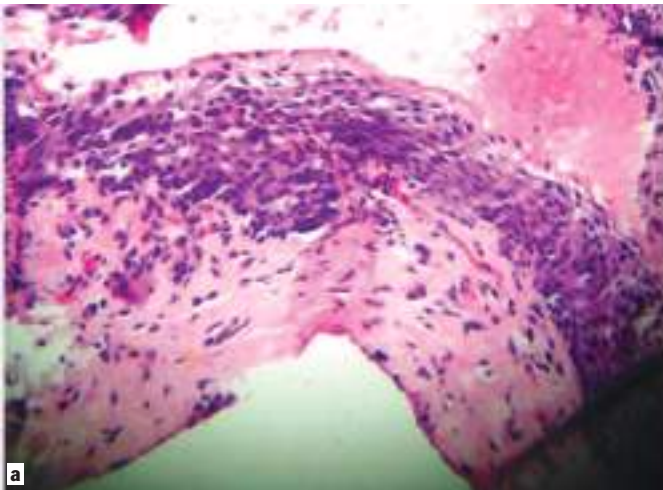


Figure 16a. Control group Pre-epithelium flattened atrophic dense stroma cells.

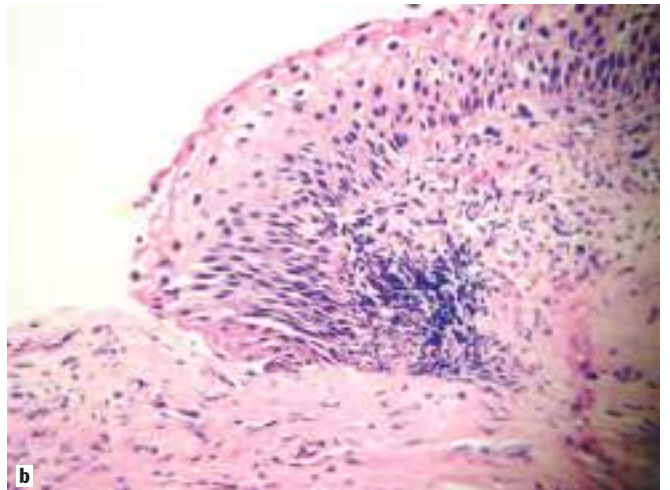


Figure 16b. Control group post-epithelium. Dense stroma sclerotic (no changes).

Recently, a vaginal probe (ThermiVa<sup>®</sup>) was developed to be able to treat the vulvovaginal tissues with this technology. TTCRF brings with it numerous advantages for the treatment of vagina laxity and GSM symptoms.

ThermiVa<sup>®</sup> has mastered the deliv-

ery of controlled-heating. The technology uses real-time temperature monitoring and regulation, ensuring the therapeutic temperature delivered to the sub-q layer is reached, but more importantly, it is maintained for the treatment timeframe (Fig. 18a-d).<sup>20</sup>

TTCRF treatment protocol in the vaginal walls has the ability to activate collagen and promote elastin formation at a molecular level. The goal of treatment is to heat vaginal/vulvar epithelium to approximately 40–45°C for a defined treatment timeframe. This

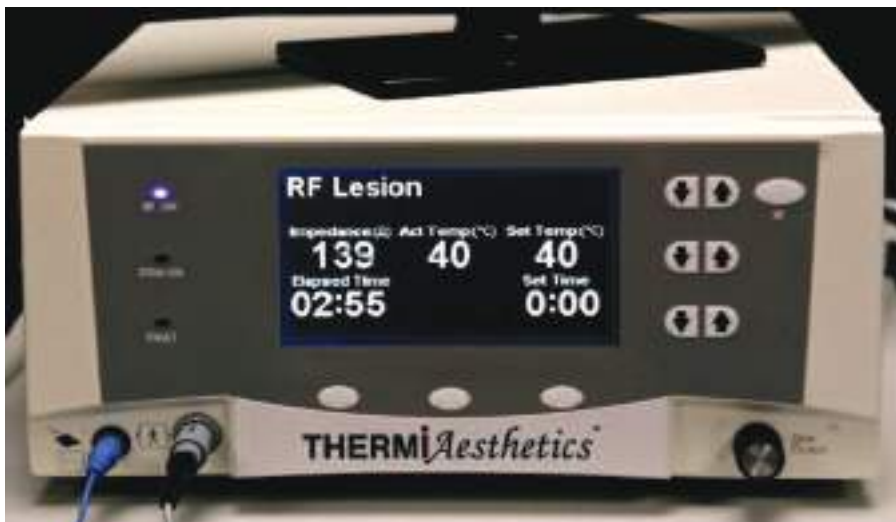

Figure 17. ThermiVa® generator (TTCRF).

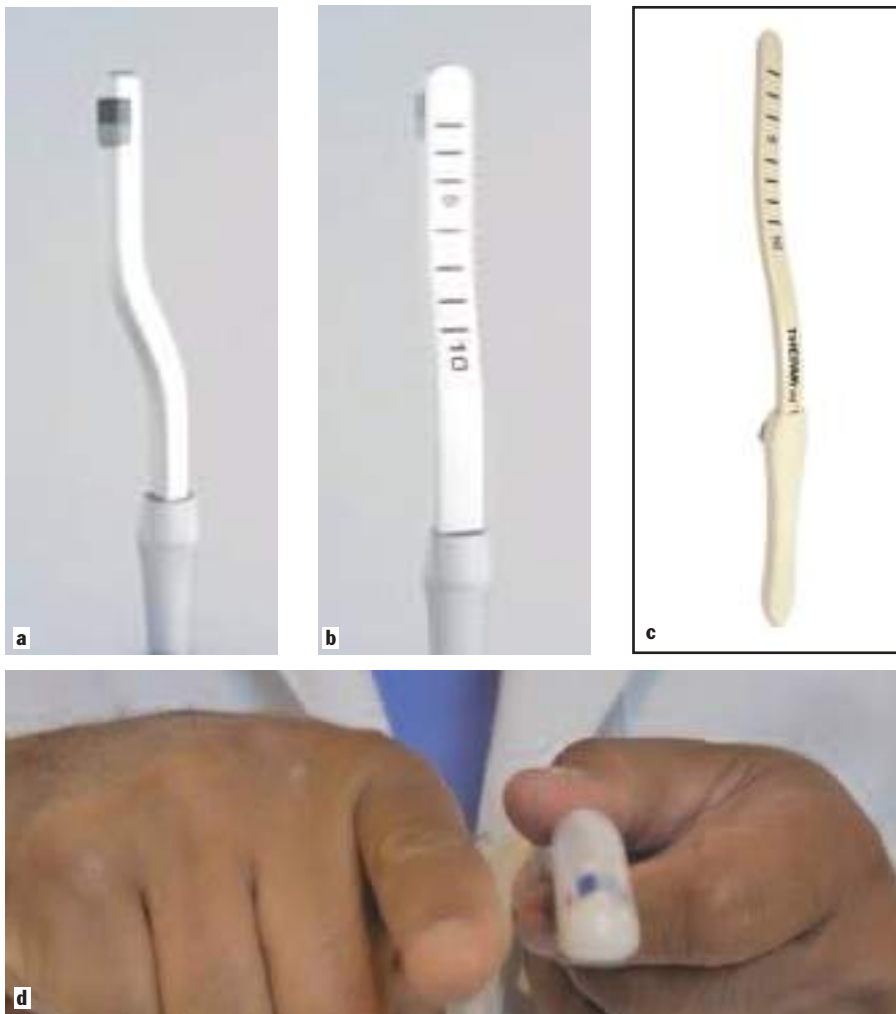


Figure 18a, b, c, and d. Special disposable design probe for TTCRF.

temperature has been shown to be necessary to stimulate fibroblasts to produce collagen de novo, which results in clinical tightening.

It is our theory, based on the histo-

logic changes seen with RF therapy to human dermis and our experience to date, that the biostimulative effect of TTCRF to the vaginal epithelium restores most vaginal functions such as

secretion, absorption, elasticity, lubrication, and vaginal epithelium thickness. We also feel that at the urethral level, it may induce important changes such as submucosal blood vessel plexus width increase and peri-urethral muscular tone recovery that are related to the urethral closure pressure mechanism and, ultimately, urinary continence in women.

Salvatore et al., demonstrated an important improvement of stress urinary incontinence in their pilot study with RF vaginal treatment.<sup>21</sup> Treatment with RF has also shown long-term safety and effectiveness for stress urinary incontinence.<sup>22</sup> This was demonstrated in the current trial as well in the treatment group that showed significant improvement in urinary health symptoms with statistically significant improvement in UDI-6 and ICQ-SF UI scores, whereas the placebo group showed no improvement in scores. This also correlated with the positive histologic changes seen in the treatment group with increased vaginal wall collagen, fibroblasts, and thickness.

It has been demonstrated that adequately delivered heat via laser<sup>23</sup> or RF to vaginal epithelium and urogenital structures generates crucial structural changes that seem to be related to vaginal trophism and extrinsic continence mechanisms of the urethra, as well as treating the symptoms related to the GSM.<sup>24,25</sup> In the current report, we confirmed these findings as we demonstrated important histological changes related to the application of TTCRF therapy to the vulvovaginal tissues. These changes were not demonstrated in the histological samples of the control group, nor did any of their symptoms improve with the blinded sham treatment. Additionally, VAS scores were also shown to significantly improve in the treatment group with no change seen in the control group. This gives even more credence to the RF therapy having a positive impact on vaginal health and sexual function.

It is important to remark that TTCRF has not been shown to adequately treat pelvic organ prolapse in advanced stages. Prolapse greater than stage II and/or more severe stress urinary leakage should still be treated with standard surgical treatment such as site-specific repair, mesh augmentation, or laparoscopic repair and SUI with

colposuspension or mid-urethral sling.

The limitations of the current study include small numbers in each group and lack of longer term follow-up. Further studies with larger sample sizes will be necessary to demonstrate specific levels of the severity of urinary incontinence, urgency/frequency symptoms, and vaginal laxity issues that can be successfully treated with TTCRF.

## CONCLUSION

Intra vaginal, non-ablative, TTCRF seems to be a promising alternative for the treatment of mild to moderate SUI and other symptoms related to the GSM. There is a group of patients with GSM that, either do not have a surgical indication, or do not want an invasive procedure. These patients would benefit from this new alternative that is non-invasive, has no surgical recovery or down-time, and carries little to no risk. It is important to remember though that GSM is a chronic condition and, therefore, long term therapy may be required. Hormonal, non-hormonal, laser, and complementary therapies are necessary to maintain positive vaginal health.

Finally, since the GSM may have a profound negative impact on QOL of postmenopausal women, women should be made aware of their diagnosis and treated with an appropriate effective therapy. Initial results demonstrate that TTCRF is a safe and effective non-surgical option for women; however, further studies with larger numbers are necessary to gain further conclusions. **STI**

## ACKNOWLEDGMENTS

The histology, clinical and statistic studies were supported by ThermiAesthetics, Irving, Texas.

## AUTHORS' DISCLOSURES

Dr. Leibaschoff is a member of the Scientific Advisory Board of ThermiAesthetics.

Dr. Moore and Dr. Miklos are clinical advisors and paid consultants for ThermiAesthetics.

All other authors have no conflicts of interest to disclose.

## REFERENCES

1. Portman DJ, Gass ML. Genitourinary syndrome of menopause: new terminology for vulvovaginal atrophy from the International Society for the Study of Women's Sexual Health and the North American Menopause Society. *Vulvovaginal Atrophy Terminology Consensus Conference Panel. Maturitas* 2014;79(3):349–54.
2. Sturdee DW, Panay N. Recommendations for the management of postmenopausal vaginal atrophy. *Climacteric* 2010;13:509–22.
3. Palacios S, Castelo-Branco C, Currie H. Update on management of genitourinary syndrome of menopause: A practical guide. *Maturitas* 2015;82(3):308–13.
4. Lin SY, Tee YT, Ng SC, et al. Changes in the extracellular matrix in the anterior vagina of women with or without prolapse. *Int Urogynecol J Pelvic Floor Dysfunct* 2007; 18:43–48.
5. Jarmy-Di Bella ZI, Girao MJ, Sartori MF, et al. Power doppler of the urethra in continent or incontinent, pre and postmenopausal women. *Int Urogynecol J Pelvic Floor Dysfunct* 2000;11:148–54.
6. Wakade DV, Nayak CS, Bhatt KD. A Study Comparing the Efficacy of Monopolar Radiofrequency and Glycolic Acid Peels in Facial Rejuvenation of Aging Skin Using Histopathology and Ultrabiomicroscopic Sonography (UBM): An Evidence Based Study. *Acta Medica (Hradec Kralove)* 2016;59(1):14–7.
7. Vanaman M, Fabi SG, Cox SE. Neck Rejuvenation Using a Combination Approach: Our Experience and a Review of the Literature. *Dermatol Surg* 2016;42 Suppl 2:S94-S100.
8. Alinsod, R. Temperature controlled radio frequency for vulva vagina laxity. *Prime North America* 2015;3/4:17–21.
9. Avery K, Donovan J, Peters T, et al. ICIQ: a brief and robust measure for evaluating the symptoms and impact of urinary incontinence. *Neurourol* 2004;23(4):322–30.
10. Price N, Jackson SR, Avery K, et al. Development and psychometric evaluation of the ICIQ Vaginal Symptoms Questionnaire: the ICIQ-VS. *BJOG* 2006;113(6):700–12.
11. Uebersax IS, Wyman JF, Shumaker SA, et al. Short forms to assess life quality and symptom distress urinary incontinence in women. *Neurourol Urodyn* 1995;14(2) 131–9.
12. Bachmann G, Phillips NA. Vaginal health prescription: possible next step in management of genitourinary syndrome of menopause. *Menopause* 2015;22(2):127–8.
13. Millhesier LS, Pauls RN, Herbst SJ, et al. Radiofrequency treatment of vagina laxity after vagina delivery: non-surgical vagina tightening. *J Sex Med* 2010;(9):3088–95.
14. Paul Abrams, Kerry Avery, Nikki Gardener, et al. Pelvic Organ Prolapse Quantification System (POP-Q) – a new era in pelvic prolapse staging. *J Urol* 2006;175(3):1063–6.
15. Lyon HO, Kiernan JA. News from the Biological Stain Commission. *Biotech Histochem.* 2008;83(6):285–8.
16. Garvey, W. Modified elastic tissue Masson trichrome stain. *Stain Technology* 1984;59(4): 213–6.
17. Dunbar S, Goldberg D. RF in cosmetic dermatology: an update. *J Drugs Dermatol* 2015;14(11):1229–38.
18. Beasley KL, Weiss RA. Radiofrequency in cosmetic dermatology. *Dermatol Clin* 2014; 32(1):79–90.
19. Key D. Comprehensive thermoregulation for the purpose of skin tightening using a novel radiofrequency treatment. *J Drug Dermatol* 2014;13(2):185–9.
20. Key D. Integration of thermal imaging with subsurface Radiofrequency thermistor heating for the purpose of skin tightening. *J Drug Dermatol* 2014;13(2):1485–9.
21. Salvatore S, Nappi RE, Zerbinati N, et al. A 12-week treatment with fractional CO 2 laser for vulvovaginal atrophy: a pilot study. *Climacteric* 2014;17(4):363–9.
22. Fritz K, Bernardy J, Tiplica GS, et al. Efficacy of monopolar radiofrequency on skin collagen remodeling: a veterinary study. *Dermatol Ther* 2015;28(3):122–5.
23. Zerbinati, N, Serati, M, Origoni, M, et al. Microscopic and ultrastructural modifications of postmenopausal atrophic vaginal mucosa after fractional carbon dioxide laser treatment. *Lasers Med Sci* 2015;30:429–36.
24. Kim HK, Kang SY, Chung YJ, et al. The recent review of the genitourinary syndrome of menopause: New era, new treatments. *J Menopausal Med.* 2015;21(2): 65–71.
25. Nappi RE, Palacios S. Impact of vulvovaginal atrophy on sexual health and quality of life at post menopause. *Climacteric* 2014 Feb;17(1):3–9